

Localisation of increased prefrontal white matter in pathological liars

YALING YANG, ADRIAN RAINE, KATHERINE L. NARR, TODD LENCZ, LORI LaCASSE, PATRICK COLLETTI and ARTHUR W. TOGA

Summary We examined white matter volumes in four prefrontal subregions using structural magnetic resonance imaging in 10 pathological liars, 14 antisocial controls, and 20 normal controls. Liars showed a relatively widespread increase in white matter (23–36%) in orbitofrontal, middle and inferior, but not superior, frontal gyri compared with antisocial and normal controls. This white matter increase may predispose some individuals to pathological lying.

Declaration of interest None. Funding detailed in Acknowledgements.

Using a symptom-based approach, we found that pathological liars have abnormally increased prefrontal white matter (Yang *et al*, 2005). It was suggested that this increase may represent a predisposition to lying. In this study it is hypothesised that pathological liars will show structural abnormalities particularly in the dorsolateral, prefrontal and orbitofrontal cortex.

METHOD

Participants were taken from a total sample of 108 community volunteers drawn from five temporary employment agencies in Los Angeles (Raine *et al*, 2000). The three groups consisted of 10 people with a history of repeated lying ('liars'), 20 normal controls who had neither antisocial personality disorder nor a history of pathological lying, and 14 'antisocial' controls matched for antisocial behaviours but with no history of pathological lying. Participants were defined as pathological liars if they fulfilled criteria for: pathological lying on the Psychopathy Checklist-Revised (PCL-R; Hare, 1991); or conning/manipulative behaviour on the PCL-R; or deceitfulness for DSM-IV antisocial personality disorder (American Psychiatric Association, 1994), or malingering (for details see Yang *et al*, 2005).

Of the 10 liars in this study, 5 were classified as malingers. Full informed, written consent was obtained from all participants in accordance with institutional review board procedures. Five brain volumes from the original sample (Yang *et al*, 2005) could not be segmented owing to irretrievable corruption on data storage. Missing data were relatively evenly distributed across groups, with two from the liar group, two from the antisocial control group and one from the normal control group.

Structural MRI was carried out on a 1.5-Telsa Philips S15/ACS (Selton, Connecticut, USA) scanner using three-dimensional T₁-weighted gradient-echo scans (for details see Yang *et al*, 2005). All image data-sets were processed with a series of preparatory steps before manual delineation of prefrontal subregions (Sowell *et al*, 1999, 2002). First, all images were anonymised to exclude personal information. Second, non-brain tissue and the cerebellum were removed from the brain volume, and signal intensity inhomogeneities were corrected (Sled & Pike, 1998). Third, fully automated tissue segmentation was applied and brain voxels were automatically classified as gray matter, white matter, or cerebrospinal fluid using a validated partial volume correction method (Shattuck *et al*, 2001). Finally, a spherical mesh surface was created using a three-dimensional active surface algorithm to facilitate identification of anatomical boundaries (MacDonald *et al*, 1994).

The parcellation of the prefrontal lobe into four subregions for each hemisphere followed the methods of Ballmaier *et al* (2004). A three-dimensional shape representation and coronal two-dimensional MRI scan of the segmentation of the prefrontal cortex of one of the participants are shown in the data supplement to the online version of this paper. All anatomical delineations were conducted by two research assistants trained by Y.Y. Unlike gray matter subregions, which are clearly defined by sulcal landmarks, white matter delineations are

arbitrary and the segmentation results should be viewed as estimated volumes. To assess interrater reliability, all anatomical regions were delineated on ten randomly chosen image data-sets; intraclass correlation coefficients ranged between 0.90 and 0.97 for gray matter and white matter in all four frontal subregions. Each of the eight subregional volumes was divided by total intracranial volume to account for potential differences in individual brain size. Since there was a lack of hemisphere effect, white matter volumes from two hemispheres were averaged to create a mean regional volume.

RESULTS

A multivariate analysis of variance (ANOVA) showed a main group effect for whole-brain-corrected white matter volume in prefrontal regions (i.e. inferior frontal, middle frontal, orbitofrontal and superior frontal cortices); $F(8, 78)=4.19$, $P=0.001$, $\eta^2=0.29$). Groups differed in the volume of white matter in the inferior ($F(2, 41)=11.09$, $P=0.001$), middle ($F(2, 41)=7.05$, $P=0.003$) and orbitofrontal cortex ($F(2, 41)=6.87$, $P=0.001$), with increased white matter in liars. However, a trend towards lower white matter volume was found in the superior frontal cortices for liars ($F(2, 41)=0.42$, $P=0.66$). Liars showed significantly increased white matter in inferior, middle and orbitofrontal cortex compared with both antisocial controls ($P=0.001$, $P=0.004$, and $P=0.006$, respectively) and normal controls ($P=0.001$, $P=0.005$, and $P=0.001$ respectively; Fig. 1). No difference was found for gray matter volume in the four subregions ($F(8, 78)=0.54$, $P=0.82$).

DISCUSSION

Following our previous finding of a prefrontal white matter increase in people who lie, cheat and manipulate others (Yang *et al*, 2005), this study found pathological liars to have increased white matter volumes in some prefrontal subregions, particularly orbitofrontal cortex (22–26% increase), inferior frontal cortex (32–36% increase) and middle frontal cortex (28–32% increase) compared with both antisocial and normal controls. An important exception was that no white matter increase was found for the superior frontal cortices. Such an increase might be expected based on findings of an fMRI study in which activation of superior frontal cortices was found during a deception task

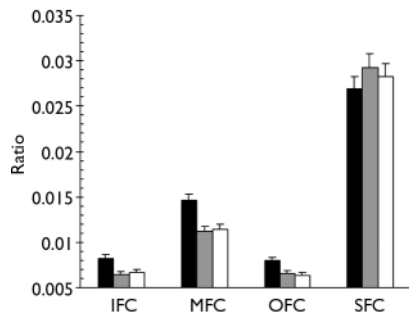


Fig. 1 Whole-brain-corrected prefrontal white matter volumes in the inferior frontal cortex (IFC), middle frontal cortex (MFC), orbitofrontal cortex (OFC), and superior frontal cortex (SFC) in pathological liars (■), normal controls (□) and antisocial controls (APD, ▒). Vertical lines indicate the standard error of the mean.

involving motor responses (Langleben *et al*, 2002). In contrast, one study using a potentially more realistic lying task involving a verbal response found prefrontal activation specifically in ventrolateral and orbitofrontal cortex, but not superior frontal cortices (Spence *et al*, 2004). Moreover, these non-superior frontal regions are most frequently shown to be activated by deception tasks (e.g. Spence *et al*, 2004; Langleben *et al*, 2005; Phan *et al*, 2005). This may in part explain why we observed white matter increases in the ventral (orbitofrontal cortex), ventrolateral (inferior frontal cortex) and inferior aspect of dorsolateral (middle frontal cortex), but not superior dorsolateral (superior frontal cortices), frontal regions in the liar group.

One interpretation of the white matter increases in the ventral and lateral non-superior frontal regions could be that a pre-existing variation in prefrontal structure may predispose individuals to engage in pathological lying. Alternatively, several studies have argued that long-term training may induce regional increases in white matter volume (Schmithorst & Wilke, 2002; Bengtsson *et al*, 2005). In the case of lying, it is conceivable that excessive lying repeatedly activates the prefrontal circuit underlying lying, resulting in permanent changes in brain morphology. This 'Pinocchio's nose' hypothesis of pathological lying could be compared with the competing predispositional hypothesis using a prospective longitudinal study assessing both white matter volume and degree of lying from childhood to adulthood.

The engagement of ventral and lateral prefrontal regions in lying may be anticipated from fMRI studies, several of which have associated these regions with executive functions crucial to successful deception, including decision-making, moral reasoning,

YALING YANG, BS, ADRIAN RAINE, DPhil, Department of Psychology, University of Southern California; KATHERINE L. NARR, PhD, David Geffen School of Medicine at UCLA; TODD LENCZ, PhD, Hillside Hospital, New York; LORI LaCASSE, BA, Department of Psychology, University of Southern California; PATRICK COLLETTI, MD, Department of Radiology, University of Southern California; ARTHUR W. TOGA, PhD, David Geffen School of Medicine at UCLA, Los Angeles, California, USA

Correspondence: Dr Yaling Yang, Department of Psychology, University of Southern California, Los Angeles, CA 90089-1061, USA. Email: yalingy@usc.edu

(First received 5 April 2006, final version 23 July 2006, accepted 3 October 2006)

rule maintenance/retrieval and response inhibition (Bunge, 2004). Although some studies showed partial activation in the superior frontal cortex when lying involved a non-vocal motor response (Langleben *et al*, 2002, 2005), this region is more associated with functions less directly linked to deception, such as spatial information processing, attention reorientation and novelty detection (Gomot *et al*, 2006). Conversely, gains in white matter volume in these prefrontal regions (in the absence of gray matter reduction) may lead to faster sharing of information within frontal-cortical circuits in pathological liars. Thus, increased white matter in these subregions of the prefrontal cortex in liars may predispose to maintaining a lifestyle of pathological lying and malingering. The use of advanced imaging techniques such as diffusion tensor imaging to assess neural connectivity (Nakamura *et al*, 2005) may allow more thorough investigation of the subtle abnormalities responsible for pathological lying.

ACKNOWLEDGEMENTS

We thank Samantha Henry, Elizabeth Culley, Donna Kha, Reimar Macaranas, Henry Wu, Lydia Lee, Sum-yan Ng and Sridhar Chadalavada for data collection and scoring. This study was supported by grants to A.R. from NIMH and the Wacker Foundation, grants from the National Center for Research Resources the NIH Roadmap for Medical Research and a NARSAD Young Investigator Award for K.L.R. and A.W.T.

REFERENCES

- American Psychiatric Association (1994)** *Diagnostic and Statistical Manual of Mental Disorders (4th edn)* (DSM-IV). Washington, DC: APA.
- Ballmaier, M., Toga, A. W., Blanton, R. E., et al (2004)** Anterior cingulate, gyrus rectus, and orbitofrontal abnormalities in elderly depressed patients: an MRI-based parcellation of the prefrontal cortex. *American Journal of Psychiatry*, **161**, 99–108.
- Bengtsson, S. L., Nagy, Z., Skare, S., et al (2005)** Extensive piano practicing has regionally specific effects on white matter development. *Nature Neuroscience*, **9**, 1148–1150.
- Bunge, S. A. (2004)** How we use rules to select actions: a review of evidence from cognitive neuroscience. *Cognitive, Affective and Behavioral Neuroscience*, **4**, 564–579.
- Gomot, M., Bernard, F. A., Davis, M. H., et al (2006)** Change detection in children with autism: an auditory event-related fMRI study. *Neuroimage*, **29**, 475–484.
- Hare, R. D. (1991)** *The Hare Psychopathy Checklist – Revised (PCL-R)*. Toronto: Multi-Health Systems.
- Langleben, D. D., Schroeder, L., Maldjian, J. A., et al (2002)** Brain activity during simulated deception: an event-related functional magnetic resonance study. *Neuroimage*, **15**, 727–732.
- Langleben, D. D., Loughhead, J. W., Bilker, W. B., et al (2005)** Telling truth from lie in individual subjects with fast event-related fMRI. *Human Brain Mapping*, **26**, 262–272.
- MacDonald, D., Avis, D. & Evans, A. (1994)** Multiple surface identification and matching in magnetic resonance images. In *Proceedings of the International Society for Optical Engineering (SPIE) Conference on Visualization in Biomedical Computing*. (ed. R. A. Robb), pp. 160–169. Rochester, MN: SPIE.
- Nakamura, M., McCarley, R. W., Kubicki, M., et al (2005)** Fronto-temporal disconnectivity in schizotypal personality disorder: a diffusion tensor imaging study. *Biological Psychiatry*, **58**, 468–378.
- Phan, K. L., Magalhaes, A., Ziemlewicz, T. J., et al (2005)** Neural correlates of telling lies: a functional magnetic resonance imaging study at 4 tesla. *Academic Radiology*, **12**, 164–172.
- Raine, A., Lencz, T., Bihrie, S., et al (2000)** Reduced prefrontal gray matter volume and reduced autonomic activity in antisocial personality disorder. *Archives of General Psychiatry*, **57**, 119–127.
- Schmithorst, V. J. & Wilke, M. (2002)** Differences in white matter architecture between musicians and non-musicians: a diffusion tensor imaging study. *Neuroscience Letters*, **327**, 57–60.
- Shattuck, D. W., Sandor-Leahy, S. R., Schaper, K. A., et al (2001)** Magnetic resonance image tissue classification using a partial volume model. *Neuroimage*, **13**, 858–876.
- Sled, J. P. & Pike, G. B. (1998)** Standing-wave and RF penetration of artifacts caused by elliptic geometry: an electrodynamic analysis of MRI. *IEEE Transactions on Medical Imaging*, **17**, 653–662.
- Sowell, E. R., Thompson, P. M., Holmes, C. J., et al (1999)** Localizing age-related changes in brain structure between childhood and adolescence using statistical parametric mapping. *Neuroimage*, **9**, 589–598.
- Sowell, E. R., Thompson, P. M., Rex, D., et al (2002)** Mapping sulcal pattern asymmetry and local cortical surface gray matter distribution in vivo: maturation in perisylvian cortices. *Cerebral Cortex*, **12**, 17–26.
- Spence, S. A., Hunter, M. D., Farrow, T. F., et al (2004)** A cognitive neurobiological account of deception: evidence from functional neuroimaging. *Philosophical Transactions of the Royal Society B: Biological Sciences*, **359**, 1755–1762.
- Yang, Y., Raine, A., Lencz, T., et al (2005)** Prefrontal white matter in pathological liars. *British Journal of Psychiatry*, **187**, 320–325.